



Assiut University
Faculty of Veterinary Medicine

**ULTRASONOGRAPHIC BIOMETRIC ANALYSIS OF
THE VENTRICLES OF OVINE HEART**

By

S.M. ABUZAID; P.F. RUMPH and R.E. CARTEE

**Reprinted From Assiut Veterinary Medical Journal
Volum 22, No. 44, January (1990)**

Dept. of Anatomy and Histology,
Fac. of Vet. Med., Suez Canal, Ismailia Egypt.
Head of Dept. Prof. Dr. A.K. Osman.

**ULTRASONOGRAPHIC BIOMETRIC ANALYSIS OF
THE VENTRICLES OF OVINE HEART**
(With One Table & 2 Figures)

By

S.M. ABUZAID; P.F. RUMPH* and R.E. CARTEE*
(Received at 18/7/1989)

تحليل حيوي بالموجات فوق صوتية لبطين القلب في الأغنام

صابر أبو زيد ، بول ريف ، روبرت كارتي

أجريت الدراسة على عشرة قلوب لخراف تامة النضج بالموجات فوق صوتية وباستخدام مصدر قوة 5 مليون ذبذبة / ثانية . وقد تم قياس سمك الجدار البطيني الأيمن والأيسر والحاجز بين بطيني الكترونيا عند مستوى متوسط بين التجويف التاجي وقبة القلب تقريباً ، ثم أجرى القياس باستخدام مقياس فيرنر وعلى نفس المستوى تقريباً . هذا وقد أوضحت الدراسة وجود إختلاف معنوي بين قياسات الجدار البطيني الأيسر فقط ، كما أوضحت الدراسة أن النسبة بين سمك الجدار البطيني الأيسر ، والأيمن والجدار بين بطيني هي 2 : 1 : 2 .

SUMMARY

The normal ovine hearts were scanned in water bath with a 5 MHz mechanical sector transducer. The thickness of the right, left and septal ventricular walls was measured ultrasonographically by electronic cursor and then physically with Vermer's caliber. There was no difference between the ultrasound and physical measurements except for the left ventricular wall where a significant difference was found ($P/0.05$). The ratio of the thickness of left ventricular wall to right ventricular wall to interventricular septum was 2:1:2.

INTRODUCTION

In the last decade, there have been tremendous advances in the speciality of veterinary cardiology. One of the most important changes has been in the general acceptance of the electrocardiogram as an essential part of the cardiac data base. The electrocardiogram tells little about the mechanical status of the heart and does not record diseases of the valves, coronary arteries, endocardium or pericardium (COHEN, 1983). The technology of ultrasound has expanded the diagnostic capabilities of the veterinarian and has provided a non-invasive method of cardiac imaging (BONAGURA,

*: Dept. of Anatomy and Histology, College of Veterinary Medicine, Auburn Uni,U.S.A.

S.M. ABUZAID *et al.*

1983). With the advent of clinical ultrasonography it is possible to image cardiac function using the M-mode echocardiography and two-dimensional echocardiography (BONAGURA; O'GRADY and HERRING, 1985). Once the ultrasonic appearance of the heart of an animal is understood, pathological conditions such as pericardial effusion, atrial and ventricular dilation and hypertrophy and abnormal cardiac motion can be appreciated.

The purposes of the present study were; to measure by ultrasonography, *in vitro*, the thickness of the right, left and septal ventricular walls of the ovine heart, and to determine whether these ultrasonographic measurements were reflective of the physical measurements.

MATERIAL and METHODS

Ten normal ovine hearts were resected just following euathanosin^(a) of the animals. The hearts were thoroughly flushed with tap water to remove clotted blood from the cardiac chambers. The aorta and pulmonary trunk were ligated. The cardiac chambers were filled with water and the various vessels to the atria were ligated.

A 5 MHz mechanical sector transducer^(b) was used to scan the cardiac ventricles in a transverse plane, nearly midway between the coronary grooves and the apex of the heart. Scanning was accomplished in a water bath with an Aquaflex Gel Pad^(c) at its base as a deep coupling medium. An electronic cursor was used for measurement of the thickness of right, left and septal ventricular walls.

The ventricular mass was bisected transversely at a point approximating the plane of ultrasonographic scan. The right, left and septal ventricular walls were measured with a Verner's caliper. Care was taken to avoid measurement at the areas of papillary muscles.

Descriptive statistics were calculated for each variable. The physical and ultrasonographic measurement data were compared using the paired student's t test.

RESULTS

The ultrasonographic images of the ovine ventricular myocardium showed a homogeneous hypoechoic pattern with hyperechoic borders adjacent to the fluid filled lumen and surrounding water bath. The lumen of the ventricles appeared relative anechoic with hyperechoic variable excursions representing the papillary muscles, moderator band and cordae tendinae (Fig. 1).

Summary descriptive statistics are shown in Table (1). The physically measured left ventricular wall thickness differed significantly ($P < 0.05$) from the ultrasound

(a) Euathanosin solution - Schering Corporation, Kenilworth, NJ.

(b) Dasonics Inc., Milpitas, CA.

(c) Parker Laboratories, Inc., Orange, NJ 07050, USA.

ULTRASONOGRAPHIC, OVINE HEART

measurement which was larger. The physical and ultrasound measurements of the right and septal ventricular wall thickness did not differ ($P/ 0.05$). The relationship of the ultrasonographic measurement of the left, septal and right ventricular wall thickness showed that in seven of 10 sheep, the left ventricular wall was slightly thicker than the interventricular septum, while the right ventricular wall was the least in all the 10 sheep (Fig. 2). The thickness ratio between the left ventricular wall to the right ventricular wall to Interventricular septum was approximately 2:1:2.

Table (1): Showing descriptive statistics of the ultrasound (US) and physical (Phy) measurements of left ventricular wall thickness (LVW), right ventricular wall thickness (RVW) and interventricular septum thickness (IVS) of 10 ovine hearts.

Measured Wall	Mean (cm)	+ SD (cm)
LVW		
US	1.99	+0.22
Phy	1.90	+0.20
RVW		
US	1.11	+/.24
Phy	1.09	+0.34
IVS		
US	1.88	+0.34
Phy	1.81	+0.19

DISCUSSION

After repeated attempts in vivo, the ovine heart was difficult to recognized due to the thoracic wall thickness and use of a 5 MHz probe. It probably could be seen when using 2.5 MHz or 3.5 MHz probe, which were not available through this work. In water bath scan, details of cardiac structures were easily recognized and did not present any special anatomical variations from those visualized in cardiac scans of other animals (BONAGURA, 1983; BONAGURA *et al.*, 1985 and COHEN, 1983). We did not find anatomical or physiological reasons explaining the difference between the ultrasound and physical measurements of the left ventricular wall ($P/ 0.017$). Therefore we consider among possible explanations differences in plane of section or cursor placement variation. In all likelihood, in vivo, ultrasound measurements of the ovine heart would show some difference from these findings, and further work is needed to obtain precise measurements of in vivo, wall thickness during all phases of cardiac motion.

REFERENCES

- Bonagura, J.D. (1983): H-mode echocardiography, basic principles. In. symposium on cardiopulmonary diagnostic techniques. *Vet. Clinics of North America*, 13(2): 299-320.

Bonagura, J.D., O'Grady, M.R. and Herring, D.S. (1985): Echocardiography, principles of interpretation. In, symposium on diagnostic ultrasound. Vet. Clinics of North America, 15(6): 1177-1194.

Cohen, R.B. (1983): Electrocardiographic techniques in clinical practice. In, symposium on cardiopulmonary diagnostic techniques. Vet. Clinics of North America, 13(2): 217-239.

Fig. (1): A transverse ultrasonogram of the ventricles of ovine heart in water bath (5 MHz probe). Cranial border (CA), caudal border (C), right ventricular wall (RVW), left ventricular wall (LVW), ventricular septum (Vs), lumen of right ventricle (RV), lumen of left ventricle (LV), papillary muscle (PM), moderator band (M), cordae tendonae (CT). Cursor shows interventricular septum thickness.

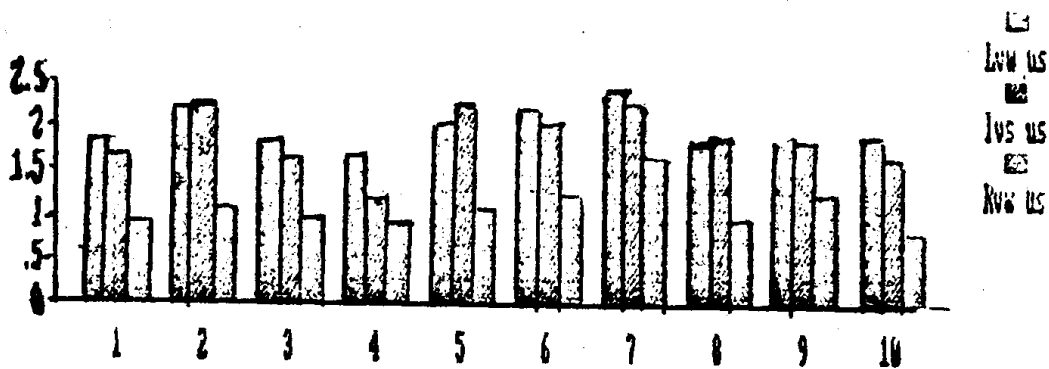


Fig. (2): Bar graph showing relationship of the left ventricular wall thickness (LVS US) and right ventricular wall thickness (RVW US) of the heart of 10 adult sheep, as measured ultrasonographically in cm.

